

Contemporary options in the management of diabetic eye disease

Consultant Ophthalmologist, Mr Hadi Zambarakji presents the symptoms of diabetic eye disease and the treatments available

Vision loss in diabetic patients is predominantly due to retinopathy, which in the more advanced stages of disease, results in new vessel growth known as proliferative diabetic retinopathy (PDR). Untreated PDR may lead to vitreal haemorrhage and retinal detachment, as well as rubeotic glaucoma, if new vessels invade the anterior segment of the eye.

The UK national screening programmes have adopted a simple classification scheme based on which a grader identifies fundus features, aimed at detecting referable retinopathy. Referrals also include patients with cataract, but macular oedema remains the most important limiting factor to visual recovery.

In relation to modifiable risk factors, the Royal College of Ophthalmologists (RCO) has recommended a target HbA1C of 48-58 mmol/mol (6.5-7.5 per cent), a systolic BP of < 130 mmHg in those with established retinopathy and the consideration of statin therapy for the prevention of macrovascular disease. Furthermore, macular oedema has been associated with the use of thiazolidinediones and current recommendation is to withdraw pioglitazone in the presence of macular oedema.

Untreated PDR may lead to vitreal haemorrhage and retinal detachment, as well as rubeotic glaucoma

Laser treatment

Ophthalmologists have long been using lasers for the treatment of diabetic macular oedema (DMO) and PDR. Recent advances include the development of portable lasers, the sub-threshold infrared 810 nm diode laser and the multi-spot lasers. The main advantage of the sub-threshold diode is that it results in minimal structural damage to the outer retina as no absorption occurs by photoreceptors. The multipot lasers however, are used because of the shorter laser pulse duration, which results in reduced pain during treatment.

Drug treatment

DMO treatment is of particular interest because of the demonstrated superior benefits of intravitreal anti-vascular endothelial growth factor (VEGF) agents including Bevacizumab (Avastin) and Ranibizumab (Lucentis) (figure 1). NICE approved the use of Ranibizumab for the treatment of DMO, in February 2013. Bevacizumab, a drug that was originally marketed for the treatment of colorectal carcinoma, is not licensed for intraocular use, despite being used extensively to treat eye disease.

Steroid treatment

Intravitreal steroid injections with Triamcinolone are rarely used nowadays but a Fluocinolone Acetonide intravitreal insert (Iluvien; Alimera Sciences) with sustained delivery for up to 36 months has recently been approved by NICE for use in chronic DMO. Increased intraocular pressure and cataract are important side effects of steroids in the eye, but the use of the iluvien insert may prove to be an attractive treatment option in eyes that are already pseudophakic.

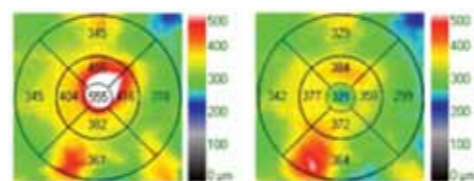


Figure 1a

Figure 1: The optical coherence image (a) shows a colour-coded map of macular (retinal) thickness (MT) in an eye with diabetic macular oedema. The grid on the left (before treatment) shows white and red colours in the centre indicating a thickened macula (MT of 555 microns) and the grid on the right (after treatment) shows bluish/green colours in the centre indicating reduced macular thickening (MT of 321 microns).

The cross section scans before (b: 02/2013) and after (c: 05/2013) treatment with Lucentis show significant resolution of cystic swellings following treatment.

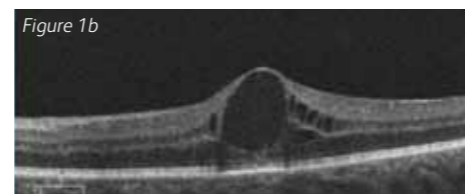


Figure 1b

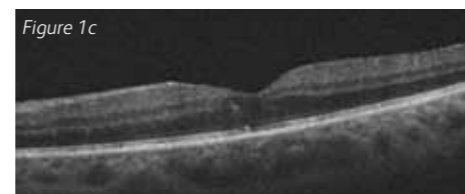


Figure 1c

What about surgery for diabetic eye disease?

Pars plana vitrectomy (PPV) is primarily indicated when advanced PDR results in vitreal haemorrhage and traction retinal detachment. Whilst the advantages of surgery vs. observation are in favour of surgery, outcomes are limited by the extent of retinal disease and macular function. Major advances include small gauge surgical instruments reducing the need for suturing, high-speed vitrectomy devices and the development of wider ranges of high quality disposable instruments. Improved visualization also improves outcomes and facilitates surgery, allowing reduced dependence on assistant help during surgery.

To find out more information about Mr Hadi Zambarakji, please visit www.practicemattersmag.co.uk/website/contributors.php

MASTERCLASS SERIES and events at The Wellington Hospital



As part of our educational programme, each year we organise a wide range of events for our GPs, Embassy Doctors, Physiotherapists and other allied healthcare professionals. This provides us with a unique opportunity to share knowledge, discuss advances in areas of practice and network with other professionals.

On Saturday 28th September, the Foot and Ankle Unit at The Wellington Hospital hosted the latest edition of the Orthopaedic Masterclass series 2013. The consultants explored a whole range of topics such as advances in ankle injuries, arthritis and sporting injuries. With over 90 attendees including GPs, physiotherapists and podiatrists, the event opened with registration and breakfast before talks on a range of topics that ran until 10:30am. Between the consultant-led talks, attendees were invited to ask questions and join discussions.

After a coffee break and an opportunity to discuss the morning's seminars, delegates were split into three groups and attended various practical, hands-on sessions exploring Arthrex demonstrations, injection techniques and braces and boots. This included an egg and spoon race in which participants wore brace boots. There was also an opportunity to test some of the latest implant designs for treatment of acute ligament and tendon injury, alongside some of the newest splints and rehabilitation aids.

The Wellington Hospital events run throughout the year and cover a variety of practices reflecting those available at our facilities. To find out more about our GP seminars, masterclasses and events, please visit the Healthcare Professionals section of The Wellington Hospital website.

